

A prospective study of physician-observed concussion during a varsity university hockey season: white matter integrity in ice hockey players. Part 3 of 4

*INGA K. KOERTE, M.D.,^{1,3} DAVID KAUFMANN, M.D.,^{1,3} ELISABETH HARTL, M.D.,¹ SYLVAIN BOUX, PH.D.,¹ OFER PASTERNAK, PH.D.,¹ MAREK KUBICKI, M.D., PH.D.,^{1,2} ALEXANDER RAUSCHER, PH.D.,⁴ DAVID K. B. LI, M.D.,⁴ SHIROY B. DADACHANJI, M.D.,⁵ JACK A. TAUNTON, M.Sc., M.D.,⁵ LORIE A. FORWELL, M.Sc.P.T.,⁶ ANDREW M. JOHNSON, PH.D.,⁷ PAUL S. ECHLIN, M.D.,⁸ AND MARTHA E. SHENTON, PH.D.^{1,2,9}

¹Psychiatry Neuroimaging Laboratory and ²Department of Radiology, Brigham and Women's Hospital, Harvard University, Boston, Massachusetts; ³Institute for Clinical Radiology, University of Munich, Ludwig-Maximilians-University, Munich, Germany; ⁴Department of Radiology and ⁵Division of Sports Medicine, Department of Medicine, University of British Columbia, Vancouver, British Columbia; ⁶Fowler Kennedy Sport Medicine Clinic and Faculty of Health Sciences, ⁷Faculty of Health Studies, The University of Western Ontario, London, Ontario; ⁸Elliott Sports Medicine Clinic, Burlington, Ontario, Canada; and ⁹Clinical Neuroscience Division, Laboratory of Neuroscience, Department of Psychiatry, VA Boston Healthcare System, Brockton, Massachusetts

Object. The aim of this study was to investigate the effect of repetitive head impacts on white matter integrity that were sustained during 1 Canadian Interuniversity Sports (CIS) ice hockey season, using advanced diffusion tensor imaging (DTI).

Methods. Twenty-five male ice hockey players between 20 and 26 years of age (mean age 22.24 ± 1.59 years) participated in this study. Participants underwent pre- and postseason 3-T MRI, including DTI. Group analyses were performed using paired-group tract-based spatial statistics to test for differences between preseason and postseason changes.

Results. Tract-based spatial statistics revealed an increase in trace, radial diffusivity (RD), and axial diffusivity (AD) over the course of 1 season. Compared with preseason data, postseason images showed higher trace, AD, and RD values in the right precentral region, the right corona radiata, and the anterior and posterior limb of the internal capsule. These regions involve parts of the corticospinal tract, the corpus callosum, and the superior longitudinal fasciculus. No significant differences were observed between preseason and postseason for fractional anisotropy.

Conclusions. Diffusion tensor imaging revealed changes in white matter diffusivity in male ice hockey players over the course of 1 season. The origin of these findings needs to be elucidated.
(<http://thejns.org/doi/abs/10.3171/2012.10.FOCUS12303>)

KEY WORDS • ice hockey • mild traumatic brain injury • axial diffusivity • diffusion tensor imaging • sports-related concussion • radial diffusivity • fractional anisotropy • Canada

SPORTS-RELATED mild TBI, also referred to as concussion, is known to have a high incidence in contact sports such as American football, boxing, wrestling, soccer, and ice hockey.^{2,18,54} Mild TBI is typically associated with acute symptomatology including dizzi-

ness, headache, visual disturbances, and cognitive impairment.^{14,41} Although the majority of athletes recover within a few days, concerns have been raised about the possible long-term effects of mild TBI on the brain's structural and functional integrity.^{4,10-13,23-25,44,46,62}

Until very recently, the diagnosis of mild TBI has been based on clinical symptoms rather than on radiological evidence. This practice has arisen from the observation that the brain often appears quite normal on CT as well as on conventional MRI.⁵⁷ However, studies that use more advanced MRI, in particular DTI, are able to detect subtle white matter changes indicating diffuse axonal injury, the most common injury observed in mild TBI.^{35,51,63}

Abbreviations used in this paper: AD = axial diffusivity; CIS = Canadian Interuniversity Sports; DTI = diffusion tensor imaging; FA = fractional anisotropy; HCEP = Hockey Concussion Education Project; MRS = magnetic resonance spectroscopy; RD = radial diffusivity; SWI = susceptibility weighted MR imaging; TBI = traumatic brain injury.

* Drs. Koerte and Kaufmann contributed equally to this work.

Diffusion tensor imaging provides information about the diffusion of water molecules, reflecting coherence, organization, and density of white matter in the brain. Fractional anisotropy is one of the most frequently used parameters and indicates the direction of the diffusion of the water molecules. In this context, a high FA value means a more unidirectional flow, whereas a low FA indicates equal water movement in virtually any direction. Higher FA thus indicates more elongated shapes of water diffusion, which are often observed in white matter, where water mainly diffuses parallel rather than perpendicular to the fibers. Fractional anisotropy is often used as a measure of white matter integrity. This is in contrast to lower FA, which is observed in, for example, CSF, where water diffuses at the same speed in all directions.

Another often-used parameter of white matter integrity is trace, also known as mean diffusivity, which measures the total diffusion in all directions. A high trace indicates that there is faster water diffusion. Two other diffusivity measures are RD and AD, which in white matter are purported to measure myelin and axonal pathology.^{1,6,7}

Diffusion changes following mild TBI are mainly characterized by increased trace/mean diffusivity^{29,50,52} and decreased FA,^{3,21,29,33,37,50} generally observed in white matter, indicating reduced white matter integrity. Only a small number of studies have reported the opposite results, an increase in FA.^{39,63} In a recent review of DTI findings in mild TBI,⁵⁷ it was noted that some studies investigating the acute and long-term course of white matter injury found an early decrease in mean diffusivity and RD directly after the injury, followed by an increase equal to or above baseline values.^{7,59–61} Animal models of brain trauma have also linked DTI parameters to histopathology, supporting the aforementioned findings in human patients.^{7,59} Moreover, diffusivity parameters have been observed to correlate with measures of executive function, attention, memory, and learning in mild TBI in general^{35,36,47,53} as well as in sports-related mild TBI.⁵²

Ice hockey players experience frequent impacts to the head.^{15,16,18–20,48,49} Previously reported concussion incidence rates have varied between 1.6 and 3.1 per 1000 athlete exposures.^{2,20} A recent study by Echlin et al.¹⁸ reported a significantly higher incidence of 21.5 per 1000 athlete exposures. Echlin et al.¹⁷ (Part 2 of 4 in this issue) report an incidence of 8.47 concussions per 1000 athlete exposures. The higher incidence rate reported in these recent studies may be due to the greater awareness of sports-related concussion among the study physicians and their superior vantage points within the arena.¹⁸ Furthermore, although the incidence rate in the Echlin et al. study documents clinically diagnosed concussions during the observation period, many of the observed and nonobserved impacts that were not diagnosed as concussions may have had a cumulative effect on the brain's functional and structural integrity.

To date, the majority of advanced MRI studies have been performed in players of other contact sports such as American football,^{9,23–27,41,42} boxing,^{22,30,44} and rugby,^{28,31,32,45} with only a small number of studies focused on ice hockey players.^{5,8,14,40,56} Bazarian and coworkers,⁵

for example, examined 1 concussed American football player, ice hockey and American football players with multiple (26–399) subconcussive hits to their heads, and 6 controls. Changes in white matter were observed most in the concussed athlete, intermediate changes in athletes with subconcussive blows to the head, and no changes at all in controls.⁵ These findings suggest that even in the absence of clinically symptomatic concussions, players are likely to evince white matter alterations if advanced neuroimaging procedures are used. The aim of this study was to investigate the effect of repetitive head impacts on white matter integrity using advanced DTI, impacts that were sustained during 1 CIS ice hockey season.

Methods

Participants and Study Protocol

Twenty-five male ice hockey players between 20 and 26 years of age (mean age 22.24 ± 1.59 years) were included in the study. All participants were part of the HCEP, a cohort study performed during a CIS ice hockey season (2011–2012). The clinical data for this study are described in detail in Echlin et al.¹⁷ (Part 2 of 4 in this issue).

Briefly, exclusion criteria were MRI exclusion criteria, as well as a history of any neurological or neuropsychiatric disease other than a previously experienced concussion. The study protocol was approved by the ethics committee within the universities at which the CIS teams were based. All participants provided written informed consent prior to the beginning of the study. Participants underwent preseason and postseason assessment including neuropsychological evaluation and advanced neuroimaging with DTI, MRS, and SWI. This study focuses on the DTI analyses, whereas the detailed description and comprehensive interpretation of concussion incidence, neuropsychological testing, as well as MRS results are presented in other papers within this issue. The men's team DTI results and both men's and women's team SWI results from this study will be presented in a future publication.

Magnetic Resonance Imaging Protocol and Data Acquisition

Data acquisition was performed on a 3-T MRI machine (Achieva, Philips) with an 8-channel head coil array. A DTI sequence with 2 averages and the following parameters was performed: 60 noncolinear diffusion directions, TR 7015 msec, TE 60 msec, matrix size 100×100 , voxel size $2.2 \times 2.2 \times 2.2$ mm, b-value = 0 and 700 sec/mm², and 70 slices.

Preprocessing of DTI

Magnetic resonance imaging data sets were examined for image quality. To remove intrascan misalignments due to eddy currents and head motion, an affine registration (FSL 4.1, part of the FMRIB Software Library, The Oxford Centre for Functional MRI of the Brain) of the diffusion-weighted images to the baseline image was performed for each participant. Gradient directions were adjusted using

White matter integrity in ice hockey players

the rotational component of the affine transformations. Nonbrain tissue and background noise were then removed from the b0 image using 3Dslicer version 3.6.2 (Surgical Planning Laboratory, Brigham and Women's Hospital). This program is freely available to the public (<http://www.slicer.org>). The diffusion tensor for each voxel was estimated using a multivariate linear fitting algorithm, and the 3 pairs of eigenvalues ($\lambda_1, \lambda_2, \lambda_3$) and eigenvectors were obtained. Voxel-wise summary parameters including FA were calculated as follows:

$$FA = \sqrt{\frac{1}{2} \frac{\sqrt{(\lambda_1 - \lambda_2)^2 + (\lambda_1 - \lambda_3)^2 + (\lambda_2 - \lambda_3)^2}}{\sqrt{(\lambda_1^2 + \lambda_2^2 + \lambda_3^2)}}}$$

$$RD = [(\lambda_2 + \lambda_3)/2], AD = [\lambda_1], \text{trace} = [\lambda_1 + \lambda_2 + \lambda_3]$$

White Matter Skeleton

Whole-brain tract-based spatial statistics,⁵⁸ a voxel-based standard-space group statistical analysis (FSL 4.1), was used to perform the whole brain analysis of white matter changes in ice hockey players between preseason and postseason. The program, as well as a detailed description of the method, can be found on the FMRIB website (<http://www.fmrib.ox.ac.uk/fsl/tbss/index.html>). Using this program, the first step involved assigning a target image by identifying the most representative FA image, taking the participants' FA data, and aligning every image to every other one. This target image was then affine-aligned to a standard space ($1 \times 1 \times 1 \text{ mm}^3$, Montreal Neurological Institute [MNI 152]). Finally, all images were coregistered into the target image. This step adjusts each data set so that the FA data of each individual fits the others exactly. These aligned FA images were then averaged to generate a cross-participant mean FA image, a 4D data set that combines all individual's FA information in 1 single file. Based on this mean FA image, the mean FA skeleton was created, which represents the center of all white matter fiber tracts common to the group. The mean FA skeleton was thresholded using an FA value of 0.3 to exclude peripheral tracts where there was significant intersubject variability and/or partial volume effects with gray matter (the borderline between the basal ganglia and the internal capsule). Each participant's aligned FA data were then projected onto the mean skeleton to create a skeletonized FA map by searching the area around the skeleton in the direction perpendicular to each tract, finding the highest local FA value, and then assigning this value to the corresponding skeletal structure. This was done to ensure that the skeleton represents the same fiber structures across the participants, bypassing possible registration inaccuracies.

Statistical Analysis

The skeletonized FA, RD, AD, and trace data were then used to perform voxel-wise statistical tests, which are based on a nonparametric approach utilizing permutation test theory to test for diffusivity differences in each participant's postseason data against preseason data. The testing was performed by the FSL Randomize program, in which random permutations were set at 5000. Paired-

group statistics of preseason versus postseason scans were performed on the FA, RD, AD, and trace data. We used threshold-free cluster enhancement to avoid choosing an arbitrary initial cluster-forming threshold; this method provides a voxel-wise significance value, p , that is fully corrected for multiple comparisons across space. We considered voxels with a p value < 0.05 as significant.

Results

Study Data

Five of the 25 male hockey players in the study experienced a clinically symptomatic concussion during the season, according to the Zurich consensus statement on Concussion in Sport.⁴³ Fourteen of the 25 players admitted that they had suffered at least 1 concussion prior to the start of the study. None of the participants had any symptoms related to acute clinical concussion when entering the study.

Six of the 25 participants were excluded because either a preseason or postseason scan was not available. Two additional participants were excluded due to motion artifacts. The analyses were therefore performed on 34 data sets of 17 hockey players, in which 3 of them had experienced a physician-diagnosed concussion during the time of the study.

Tract-Based Spatial Statistics

The paired-group test was performed on the 17 preseason and 17 postseason data sets. Findings revealed a significant increase in trace, AD, and RD in the postseason scans ($p < 0.05$). Compared with preseason data, postseason images showed higher trace, AD, and RD values in the right precentral region, the right corona radiata, and the anterior and posterior limb of the internal capsule. This region contains pathways of the corpus callosum, the right superior longitudinal fasciculus, and the right corticospinal tract. The spatial distribution of the clusters with increased diffusivity measures is presented in Fig. 1a–c. The individual's measures in the significant clusters, as revealed by tract-based spatial statistics, are displayed in the respective scatter plots in Fig. 1d–f. There was no significant difference for FA between pre- and postseason scans. Table 1 lists the mean percentage increase in diffusivity parameters from preseason to postseason (AD 5.2%, range -1.96% to 12.07% ; RD 7.89%, range -4.75% to 18.09% ; trace 5.78%, range -1.72% to 13.98%) as well as the change in percentage for each individual. A more pronounced increase in RD was found for the 3 concussed athletes compared with the other players ($p = 0.047$, Mann-Whitney U-test). No statistically significant difference was found for AD and trace values. When testing for higher diffusivity in preseason versus postseason images we found higher RD, AD, and trace values in the left hemisphere but not in the right (data not shown). Figure 2 displays an example of the corticospinal tract in each hemisphere as assessed using tractography.

Discussion

This study showed an increase in diffusivity in ma-

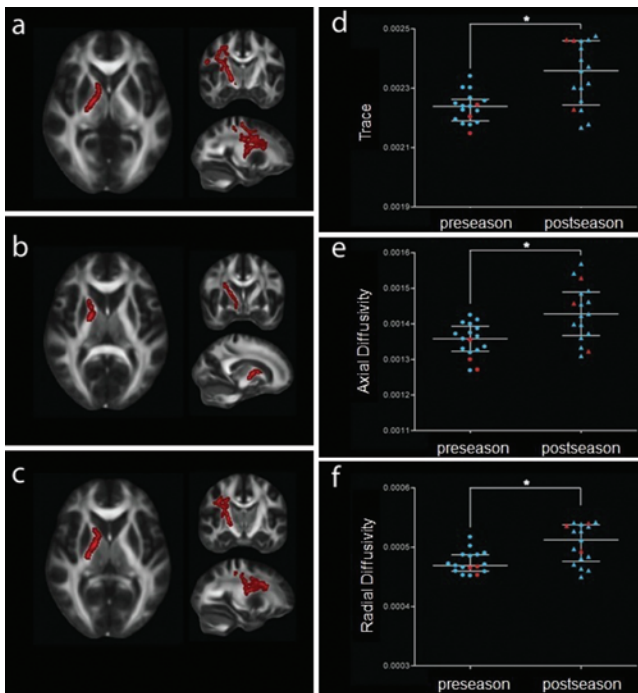


Fig. 1. Results of the tract-based spatial statistical analysis (**a–c**) and respective scatter plots of participant measures (**d–f**). Voxels highlighted in *red* demonstrate significantly increased trace value (**a**), AD (**b**), and RD (**c**) on postseason images when compared with preseason images. Voxels are thickened into local tracts and overlaid on the group mean FA image. Images are shown according to radiological convention (*right* = participants' left). Compared with preseason images, postseason images showed higher values for trace (median [interquartile range] 0.00224 [0.00006] vs 0.00236 [0.0008], respectively), AD (0.00136 [0.00006] vs 0.00143 [0.001], respectively), and RD (0.000469 [0.00003] vs 0.000512 [0.00006], respectively). Participants who experienced a clinically symptomatic concussion (Cases 1, 4, and 17) during the season are indicated in *red* in the scatter plots. Importantly, note that 2 of the 3 concussed players moved from the middle or lower portion of the distribution at preseason to the top of the range at postseason.

major white matter tracts in the right hemisphere over the course of 1 ice hockey season, suggesting altered white matter integrity in ice hockey players. Tract-based spatial statistics revealed large clusters with increased trace-, RD-, and AD-containing fibers of the corpus callosum, the right corticospinal tract, the right internal capsule, and the right superior longitudinal fasciculus. These results may indicate alterations in white matter, such as reduced thickness of the myelin sheaths and/or changes to the axon itself.^{7,62}

The findings reported in our cohort of hockey players are similar to those previously published on mild TBI in other contact sports. These studies have reported abnormalities in a variety of brain regions, including the corona radiata,^{29,39,50} uncinate fasciculus,^{21,39} corpus callosum,^{39,50,64} corticospinal tract,³³ internal capsule,^{3,29,50} and superior longitudinal fasciculus.²¹ Interestingly, the difference in diffusivity measures between preseason and postseason was significant even though only 3 of the study participants included in the statistical analysis had experienced a clinically symptomatic concussion over the course of the season. This suggests that white matter al-

TABLE 1: Percentage change from preseason to postseason in the diffusivity measures for each of the 17 participants in the study

Case No.	AD	RD	Trace
1*	3.93	11.57	5.43
2	2.70	-4.75	0.80
3	3.26	7.68	4.04
4*	9.64	18.09	12.33
5	5.12	0.37	6.97
6	11.76	11.38	12.76
7	-0.38	4.96	-1.72
8	6.40	8.84	7.00
9	2.93	3.61	2.49
10	2.92	13.86	3.38
11	-1.96	2.10	-1.32
12	7.42	11.34	8.16
13	7.16	11.03	7.80
14	12.07	15.23	11.10
15	2.35	-1.46	0.14
16	2.98	3.64	5.00
17*	10.02	16.67	13.98
mean	5.20	7.89	5.78

* Participants who experienced a concussion during the season. The values for 2 of these players (Cases 4 and 17) are greater than the mean percentage change.

terations occur even in the absence of a diagnosed concussion, which is in accordance with other studies in contact sports where concerns have been raised about the cumulative effects of frequent brain trauma.^{4,10–13,23–25,44,46,62}

Diffusion tensor imaging has only recently been applied to investigating brain abnormalities in mild TBI, and to date, most published studies have only analyzed FA. Only a small number of studies exist that have included mean diffusivity in addition to FA (the review by Shenton et al. in 2012⁵⁷ lists 22), and an even smaller number of more recent studies exist that have analyzed RD and/or AD in addition to mean diffusivity and FA (Shenton et al.⁵⁷ lists 8). Diffusion changes indicating altered white matter integrity following mild TBI are mainly characterized by decreased FA^{3,21,29,33,37,50} and increased mean diffusivity,^{29,50,52} and in the more recent studies, increased RD has also been found.^{33,34} In addition, animal models have shown increased RD to be associated with postinjury demyelination.⁶¹ Our results showed an increase in trace/mean diffusivity, RD, and AD. However, we did not find a significant decrease in FA. This may be due to the fact that we compared individuals before and after the season and did not use a comparison with a control group. Moreover, tract-based spatial statistics compares all voxels that are part of the entire white matter skeleton between the two groups while adjusting for multiple comparisons. Therefore, tract-based spatial statistics is known to be very conservative and only shows highly significant differences between groups.

Previously published studies mainly report white



Fig. 2. Tractography of the corticospinal tract of the left and right hemisphere. Tracts were obtained with the Unscented Kalman filter–based 2-tensor tractography algorithm^{38,55} to trace fiber paths of the entire brain. Fibers were separately filtered through the precentral gyrus and the anterior pons for each side.

matter changes in both hemispheres, although findings of asymmetry have been observed in some studies.⁹ In our cohort, statistically significant effects were only visible in the right hemisphere. This might be due to the fact that we compared preseason and postseason assessment instead of also comparing hockey players to a control group, where we might have found a pronounced overall effect rather than a localized effect within the right hemisphere. Additionally, 56% of all participants reported at least 1 previously sustained concussion before entering the study. Therefore, the results of this study may only reflect additional changes in white matter alterations over the course of 1 season, because the effects of mild TBI might have already been present in the majority of participants. In this context, the right hemisphere may be more susceptible to diffuse axonal injury than the left, where changes might not be as pronounced within the investigated group of athletes. However, the interpretation of findings of white matter alterations in the right hemisphere is at best speculative. Further studies are needed, including complete information regarding the laterality of sustained impacts to the head, which may provide the necessary link between injury mechanism and the location of white matter alterations in sports-related concussion.

The limitations of this study include the small sample size and the lack of a control group of healthy athletes taking part in noncontact sports. The tract-based spatial statistics findings of higher RD, AD, and trace values in the left hemisphere for the preseason data when compared with postseason data were not predicted and are difficult to interpret. Gross image artifacts and magnet inhomogeneities have been ruled out, but further studies including a control group are needed to confirm this finding and to evaluate its possible significance. General limitations of tract-based spatial statistics include the fact that it only evaluates voxels belonging to white matter and thus gray matter is not included for investigation.

Conclusions

Diffusion tensor imaging revealed changes in white matter diffusivity in ice hockey players over the course of 1 season. The origin of these changes needs to be elucidated. One possible explanation may be the effect of brain trauma, but an effect of training could also contribute. Future studies are needed to confirm these findings in both male and female athletes and to relate DTI findings to other advanced neuroimaging techniques and to neurocognitive function.

Disclosure

Inga Koerte was supported by the Else Kröner-Fresenius Stiftung, Germany. Funding for this work was provided to Dr. Echlin by the Ontario Trillium Foundation, the Dave Irwin Foundation for Brain Injury, the Ontario Neurotrauma Foundation, and Air Canada. This work was part of a doctoral thesis by Dr. Kaufmann.

Author contributions to the study and manuscript preparation include the following. Conception and design: Echlin, Kaufmann, Hartl, Bouix, Pasternak, Kubicki, Forwell, Johnson, Shenton. Acquisition of data: Echlin, Rauscher, Li, Dadachanji, Taunton. Analysis and interpretation of data: Echlin, Koerte, Kaufmann, Hartl, Bouix, Pasternak, Kubicki, Forwell, Johnson, Shenton. Drafting the article: Echlin, Koerte, Kaufmann, Hartl, Bouix, Pasternak, Kubicki, Forwell, Johnson, Shenton. Critically revising the article: all authors. Reviewed submitted version of manuscript: all authors. Statistical analysis: Echlin, Koerte, Kaufmann, Hartl, Bouix, Kubicki, Johnson. Administrative/technical/material support: Echlin, Pasternak, Rauscher, Li, Forwell, Shenton. Study supervision: Echlin, Koerte, Hartl, Rauscher, Li, Dadachanji, Taunton, Forwell, Shenton.

Acknowledgments

The authors acknowledge the players and staffs of two CIS varsity ice hockey teams for their participation in the HCEP, and also the participating physicians, observers, and volunteers for their contributions to the HCEP. The authors would also like to acknowledge the contributions of the University of British Columbia MRI Center and all of the associated researchers and employees, especially Ms. Trudy Harris and Ms. Linda Chandler.

References

1. Acosta-Cabronero J, Williams GB, Pengas G, Nestor PJ: Absolute diffusivities define the landscape of white matter degeneration in Alzheimer's disease. *Brain* **133**:529–539, 2010
2. Agel J, Dick R, Nelson B, Marshall SW, Dompier TP: Descriptive epidemiology of collegiate women's ice hockey

- injuries: National Collegiate Athletic Association Injury Surveillance System, 2000–2001 through 2003–2004. **J Athl Train** **42**:249–254, 2007
3. Arfanakis K, Haughton VM, Carew JD, Rogers BP, Dempsey RJ, Meyerand ME: Diffusion tensor MR imaging in diffuse axonal injury. **AJNR Am J Neuroradiol** **23**:794–802, 2002
 4. Baugh CM, Stamm JM, Riley DO, Gavett BE, Shenton ME, Lin A, et al: Chronic traumatic encephalopathy: neurodegeneration following repetitive concussive and subconcussive brain trauma. **Brain Imaging Behav** **6**:244–254, 2012
 5. Bazarian JJ, Zhu T, Blyth B, Borrino A, Zhong J: Subject-specific changes in brain white matter on diffusion tensor imaging after sports-related concussion. **Magn Reson Imaging** **30**:171–180, 2012
 6. Beaulieu C: The basis of anisotropic water diffusion in the nervous system—a technical review. **NMR Biomed** **15**:435–455, 2002
 7. Budde MD, Janes L, Gold E, Turtzo LC, Frank JA: The contribution of gliosis to diffusion tensor anisotropy and tractography following traumatic brain injury: validation in the rat using Fourier analysis of stained tissue sections. **Brain** **134**:2248–2260, 2011
 8. Chen JK, Johnston KM, Frey S, Petrides M, Worsley K, Ptito A: Functional abnormalities in symptomatic concussed athletes: an fMRI study. **Neuroimage** **22**:68–82, 2004
 9. Cubon VA, Putukian M, Boyer C, Dettwiler A: A diffusion tensor imaging study on the white matter skeleton in individuals with sports-related concussion. **J Neurotrauma** **28**:189–201, 2011
 10. De Beaumont L, Brisson B, Lassonde M, Jolicoeur P: Long-term electrophysiological changes in athletes with a history of multiple concussions. **Brain Inj** **21**:631–644, 2007
 11. De Beaumont L, Lassonde M, Leclerc S, Théoret H: Long-term and cumulative effects of sports concussion on motor cortex inhibition. **Neurosurgery** **61**:329–337, 2007
 12. De Beaumont L, Mongeon D, Tremblay S, Messier J, Prince F, Leclerc S, et al: Persistent motor system abnormalities in formerly concussed athletes. **J Athl Train** **46**:234–240, 2011
 13. De Beaumont L, Théoret H, Mongeon D, Messier J, Leclerc S, Tremblay S, et al: Brain function decline in healthy retired athletes who sustained their last sports concussion in early adulthood. **Brain** **132**:695–708, 2009
 14. Echemendia RJ, Putukian M, Mackin RS, Julian L, Shoss N: Neuropsychological test performance prior to and following sports-related mild traumatic brain injury. **Clin J Sport Med** **11**:23–31, 2001
 15. Echlin PS: Concussion education, identification, and treatment within a prospective study of physician-observed junior ice hockey concussions: social context of this scientific intervention. **Neurosurg Focus** **29**(5):E7, 2010
 16. Echlin PS, Johnson AM, Riverin S, Tator CH, Cantu RC, Cusimano MD, et al: A prospective study of concussion education in 2 junior ice hockey teams: implications for sports concussion education. **Neurosurg Focus** **29**(5):E6, 2010
 17. Echlin PS, Skopelja EN, Worsley R, Dadachanji SB, Lloyd-Smith DR, Taunton JA, et al: A prospective study of physician-observed concussion during a varsity university ice hockey season: incidence and neuropsychological changes. Part 2 of 4. **Neurosurg Focus** **33**(6):E2, 2012
 18. Echlin PS, Tator CH, Cusimano MD, Cantu RC, Taunton JE, Upshur RE, et al: A prospective study of physician-observed concussions during junior ice hockey: implications for incidence rates. **Neurosurg Focus** **29**(5):E4, 2010
 19. Echlin PS, Tator CH, Cusimano MD, Cantu RC, Taunton JE, Upshur RE, et al: Return to play after an initial or recurrent concussion in a prospective study of physician-observed junior ice hockey concussions: implications for return to play after a concussion. **Neurosurg Focus** **29**(5):E5, 2010
 20. Flik K, Lyman S, Marx RG: American collegiate men's ice hockey: an analysis of injuries. **Am J Sports Med** **33**:183–187, 2005
 21. Geary EK, Kraus MF, Pliskin NH, Little DM: Verbal learning differences in chronic mild traumatic brain injury. **J Int Neuropsychol Soc** **16**:506–516, 2010
 22. Gronwall D, Wrightson P: Cumulative effect of concussion. **Lancet** **2**:995–997, 1975
 23. Guskiewicz KM, Marshall SW, Bailes J, McCrea M, Cantu RC, Randolph C, et al: Association between recurrent concussion and late-life cognitive impairment in retired professional football players. **Neurosurgery** **57**:719–726, 2005
 24. Guskiewicz KM, Marshall SW, Bailes J, McCrea M, Harding HP Jr, Matthews A, et al: Recurrent concussion and risk of depression in retired professional football players. **Med Sci Sports Exerc** **39**:903–909, 2007
 25. Guskiewicz KM, McCrea M, Marshall SW, Cantu RC, Randolph C, Barr W, et al: Cumulative effects associated with recurrent concussion in collegiate football players: the NCAA Concussion Study. **JAMA** **290**:2549–2555, 2003
 26. Henry LC, Tremblay J, Tremblay S, Lee A, Brun C, Lepore N, et al: Acute and chronic changes in diffusivity measures after sports concussion. **J Neurotrauma** **28**:2049–2059, 2011
 27. Henry LC, Tremblay S, Leclerc S, Khiat A, Boulanger Y, Ellemberg D, et al: Metabolic changes in concussed American football players during the acute and chronic post-injury phases. **BMC Neurol** **11**:105, 2011
 28. Hollis SJ, Stevenson MR, McIntosh AS, Shores EA, Collins MW, Taylor CB: Incidence, risk, and protective factors of mild traumatic brain injury in a cohort of Australian nonprofessional male rugby players. **Am J Sports Med** **37**:2328–2333, 2009
 29. Inglese M, Makani S, Johnson G, Cohen BA, Silver JA, Gonen O, et al: Diffuse axonal injury in mild traumatic brain injury: a diffusion tensor imaging study. **J Neurosurg** **103**:298–303, 2005
 30. Jordan BD, Zimmerman RD: Computed tomography and magnetic resonance imaging comparisons in boxers. **JAMA** **263**:1670–1674, 1990
 31. Kemp SP, Hudson Z, Brooks JH, Fuller CW: The epidemiology of head injuries in English professional rugby union. **Clin J Sport Med** **18**:227–234, 2008
 32. King DA, Hume PA, Milburn P, Gianotti S: Rugby league injuries in New Zealand: a review of 8 years of Accident Compensation Corporation injury entitlement claims and costs. **Br J Sports Med** **43**:595–602, 2009
 33. Kraus MF, Susmaras T, Caughlin BP, Walker CJ, Sweeney JA, Little DM: White matter integrity and cognition in chronic traumatic brain injury: a diffusion tensor imaging study. **Brain** **130**:2508–2519, 2007
 34. Kumar R, Gupta RK, Husain M, Chaudhry C, Srivastava A, Saksena S, et al: Comparative evaluation of corpus callosum DTI metrics in acute mild and moderate traumatic brain injury: its correlation with neuropsychometric tests. **Brain Inj** **23**:675–685, 2009
 35. Lipton ML, Gellella E, Lo C, Gold T, Ardekani BA, Shifteh K, et al: Multifocal white matter ultrastructural abnormalities in mild traumatic brain injury with cognitive disability: a voxel-wise analysis of diffusion tensor imaging. **J Neurotrauma** **25**:1335–1342, 2008
 36. Lipton ML, Gulko E, Zimmerman ME, Friedman BW, Kim M, Gellella E, et al: Diffusion-tensor imaging implicates prefrontal axonal injury in executive function impairment following very mild traumatic brain injury. **Radiology** **252**:816–824, 2009
 37. Little DM, Kraus MF, Joseph J, Geary EK, Susmaras T, Zhou XJ, et al: Thalamic integrity underlies executive dysfunction in traumatic brain injury. **Neurology** **74**:558–564, 2010
 38. Malcolm JG, Shenton ME, Rathi Y: Neural tractography using an unscented Kalman filter. **Inf Process Med Imaging** **21**:126–138, 2009

White matter integrity in ice hockey players

39. Mayer AR, Ling J, Mannell MV, Gasparovic C, Phillips JP, Doezema D, et al: A prospective diffusion tensor imaging study in mild traumatic brain injury. **Neurology** **74**:643–650, 2010
40. McAllister TW, Flashman LA, Maerlender A, Greenwald RM, Beckwith JG, Tosteson TD, et al: Cognitive effects of one season of head impacts in a cohort of collegiate contact sport athletes. **Neurology** **78**:1777–1784, 2012
41. McCrea M, Guskiewicz KM, Marshall SW, Barr W, Randolph C, Cantu RC, et al: Acute effects and recovery time following concussion in collegiate football players: the NCAA Concussion Study. **JAMA** **290**:2556–2563, 2003
42. McCrea M, Hammeke T, Olsen G, Leo P, Guskiewicz K: Unreported concussion in high school football players: implications for prevention. **Clin J Sport Med** **14**:13–17, 2004
43. McCrory P, Meeuwisse W, Johnston K, Dvorak J, Aubry M, Molloy M, et al: Consensus Statement on Concussion in Sport: the 3rd International Conference on Concussion in Sport held in Zurich, November 2008. **Br J Sports Med** **43** (Suppl 1):i76–i90, 2009
44. McCrory P, Zazryn T, Cameron P: The evidence for chronic traumatic encephalopathy in boxing. **Sports Med** **37**:467–476, 2007
45. McIntosh AS, McCrory P, Finch CF, Best JP, Chalmers DJ, Wolfe R: Does padded headgear prevent head injury in rugby union football? **Med Sci Sports Exerc** **41**:306–313, 2009
46. McKee AC, Cantu RC, Nowinski CJ, Hedley-Whyte ET, Gavett BE, Budson AE, et al: Chronic traumatic encephalopathy in athletes: progressive tauopathy after repetitive head injury. **J Neuropathol Exp Neurol** **68**:709–735, 2009
47. Messé A, Caplain S, Paradot G, Garrigue D, Mineo JF, Soto Ares G, et al: Diffusion tensor imaging and white matter lesions at the subacute stage in mild traumatic brain injury with persistent neurobehavioral impairment. **Hum Brain Mapp** **32**:999–1011, 2011
48. Mihalik JP, Blackburn JT, Greenwald RM, Cantu RC, Marshall SW, Guskiewicz KM: Collision type and player anticipation affect head impact severity among youth ice hockey players. **Pediatrics** **125**:e1394–e1401, 2010
49. Mihalik JP, Guskiewicz KM, Marshall SW, Blackburn JT, Cantu RC, Greenwald RM: Head impact biomechanics in youth hockey: comparisons across playing position, event types, and impact locations. **Ann Biomed Eng** **40**:141–149, 2012
50. Miles L, Grossman RI, Johnson G, Babb JS, Diller L, Inglese M: Short-term DTI predictors of cognitive dysfunction in mild traumatic brain injury. **Brain Inj** **22**:115–122, 2008
51. Niogi SN, Mukherjee P: Diffusion tensor imaging of mild traumatic brain injury. **J Head Trauma Rehabil** **25**:241–255, 2010
52. Niogi SN, Mukherjee P, Ghajar J, Johnson C, Kolster RA, Sarkar R, et al: Extent of microstructural white matter injury in postconcussive syndrome correlates with impaired cognitive reaction time: a 3T diffusion tensor imaging study of mild traumatic brain injury. **AJNR Am J Neuroradiol** **29**:967–973, 2008
53. Niogi SN, Mukherjee P, Ghajar J, Johnson CE, Kolster R, Lee H, et al: Structural dissociation of attentional control and memory in adults with and without mild traumatic brain injury. **Brain** **131**:3209–3221, 2008
54. Powell JW, Barber-Foss KD: Traumatic brain injury in high school athletes. **JAMA** **282**:958–963, 1999
55. Rathi Y, Kubicki M, Bouix S, Westin CF, Goldstein J, Seidman L, et al: Statistical analysis of fiber bundles using multi-tensor tractography: application to first-episode schizophrenia. **Magn Reson Imaging** **29**:507–515, 2011
56. Rishiraj N, Lloyd-Smith R, Lorenz T, Niven B, Michel M: University men's ice hockey: rates and risk of injuries over 6-years. **J Sports Med Phys Fitness** **49**:159–166, 2009
57. Shenton ME, Hamoda HM, Schneiderman JS, Bouix S, Pasternak O, Rathi Y, et al: A review of magnetic resonance imaging and diffusion tensor imaging findings in mild traumatic brain injury. **Brain Imaging Behav** **6**:137–192, 2012
58. Smith SM, Jenkinson M, Johansen-Berg H, Rueckert D, Nichols TE, Mackay CE, et al: Tract-based spatial statistics: voxelwise analysis of multi-subject diffusion data. **Neuroimage** **31**:1487–1505, 2006
59. Song SK, Sun SW, Ju WK, Lin SJ, Cross AH, Neufeld AH: Diffusion tensor imaging detects and differentiates axon and myelin degeneration in mouse optic nerve after retinal ischemia. **Neuroimage** **20**:1714–1722, 2003
60. Song SK, Sun SW, Ramsbottom MJ, Chang C, Russell J, Cross AH: Demyelination revealed through MRI as increased radial (but unchanged axial) diffusion of water. **Neuroimage** **17**:1429–1436, 2002
61. Song SK, Yoshino J, Le TQ, Lin SJ, Sun SW, Cross AH, et al: Demyelination increases radial diffusivity in corpus callosum of mouse brain. **Neuroimage** **26**:132–140, 2005
62. Stern RA, Riley DO, Daneshvar DH, Nowinski CJ, Cantu RC, McKee AC: Long-term consequences of repetitive brain trauma: chronic traumatic encephalopathy. **PM R** **3** (10 Suppl 2):S460–S467, 2011
63. Wilde EA, McCauley SR, Hunter JV, Bigler ED, Chu Z, Wang ZJ, et al: Diffusion tensor imaging of acute mild traumatic brain injury in adolescents. **Neurology** **70**:948–955, 2008

Manuscript submitted September 17, 2012.

Accepted October 22, 2012.

Please include this information when citing this paper: DOI: 10.3171/2012.10.FOCUS12303.

Address correspondence to: Paul S. Echlin, M.D., Elliott Sports Medicine Clinic, 1100 Walkers Line, Suite 2, Burlington, Ontario, Canada L7N 2G3. email: psechlin@gmail.com.